



A Rare Malign Tumor of The Lung; Low-Grade Fibromyxoid Sarcoma: Case Report

Akciğerin Nadir Malign Tümörü; Düşük Dereceli Fibromiksoid Sarkom: Olgu Sunumu

Akciğerin Düşük Dereceli Fibromiksoid Sarkomu / Low-Grade Fibromyxoid Sarcoma of the Lung

Ismail Cuneyt Kurul¹, Ali Celik², Nalan Akyurek³, Ilknur Teber¹, Mustafa Demiroz¹, Leyla Memis³

¹Department of Thoracic Surgery, Gazi University Medical School, Besevler, ²Atatürk Center For Chest Disease and Thoracic Surgery
³Department of Pathology, Gazi University Medical School, Besevler, Ankara, Turkey

Özet

Akciğerin primer sarkomları nadir görülmektedir. Akciğer yerleşimli düşük dereceli fibromiksoid sarkom (LGFMS) ise daha da nadirdir. Akciğer grafisinde solda tespit edilen kitle lezyonu nedeni ile kliniğimize başvuran 16 yaşında bir kız çocuğunda, akciğerden köken alan düşük dereceli fibromiksoid sarkom (LGFMS) olgusunu sunuyoruz. Hastaya sol torakotomi ile cerrahi eksizyon ve lenf nodu diseksiyonu yapıldı. Tümör mikroskopisinde; atipi göstermeyen fibroblastik iğsi hücrelerin, fibröz ve miksoid alanlarda helezonik veya lineer dizilim gösterdiği izlendi. Hasta cerrahi sonrası 2 yıldır herhangi bir hastalık belirtisi olmaksızın yaşamını sürdürmektedir. Her ne kadar LGFMS'ler histolojik olarak iyi huylu olarak nitelendirilseler de lokal rekürrens ve geç metastazlar sıklıkla bildirilmektedir. Düşük dereceli fibromiksoid sarkom muhtemelen az bilinen bir pulmoner neoplazi olup iğsi hücreli neoplazilerin ayırıcı tanısında akılda tutulmalıdır.

Anahtar Kelimeler

Düşük Dereceli Fibromiksoid Sarkom; Akciğer; Cerrahi; Histopatoloji

Abstract

Primary sarcomas of lung are uncommon, and low-grade fibromyxoid sarcoma (LGFMS) located within the lung is exceedingly rare. We report an LGFMS arising from the lung in a 16-year old-girl. She was referred to our clinic for evaluation of the mass lesion found on left side of her chest roentgenogram. Surgical excision and lymph node dissection was performed via left thoracotomy. The microscopic appearance of the tumor exhibit bland fibroblastic spindle cells with a whorled or linear arrangement in fibrous and myxoid areas. The patient has remained well with no evidence of disease 2 years after. Although LGFMS has a deceptively benign histologic appearance, local recurrence and late metastases have frequently been reported. Low-grade fibromyxoid sarcoma is probably an underrecognized lung neoplasm and should be considered in the differential diagnosis of spindle cell neoplasms.

Keywords

Low-Grade Fibromyxoid Sarcoma; Lung, Surgery; Histopathology

DOI: 10.4328/JCAM.546

Received: 14.12.2010 Accepted: 02.01.2011 Printed: 01.07.2012 J Clin Anal Med 2012;3(3): 356-8

Corresponding Author: Ali Celik, Atatürk Center For Chest Disease and Thoracic Surgery, Department of Thoracic Surgery, Kecioren, 06280, Ankara, Turkey.
T.: +905304045467 F.: +90312 3552135 E-Mail: alicelik78@gmail.com

Introduction

Sarcomas are uncommon lesions of lung, constitutes less than 0.5% of the malign lung tumors [1]. Low-grade fibromyxoid sarcomas most frequently occur in soft tissues of the proximal extremities and rarely are described as a primary neoplasm within the lung [2]. Complete resection is very important as other malign tumors. Adjuvant chemotherapy or radiotherapy is indicated for incomplete resection and lymph node invasion. We report herein the LGFMS arising from the lung parenchyma in a 16-year-old girl.

Case Report

A 16-year-old female presented with a history of pain on both arms and legs. Chest X-ray revealed a 10x8 cm circular, homogenous mass lesion on left middle-inferior zone (Figure 1a.) and the patient was referred to our clinic. On admission whole respiratory and general systemic physical examination was normal. Thorax CT showed a well-circumscribed, homogenous mass measuring 10x8 cm that was located at left inferosuperior segment, nearby the major fissur (Figure 1b).

The pathologic examination of transthoracic needle biopsy was interpreted as spindle cell tumor consisting with malignant. As no other primer focus has found after a whole systemic scanning of the patient, it's thought as this lesion to be a primary lung tumor. Left lower lobectomy with mediastinal lymph node dissection performed via left posterolateral thoracotomy. In post-operative period, patient was uneventful and extubated on sixth day of the operation.

In the lobectomy specimen, a well-circumscribed, homogeneous gray-white appearance tumor, measuring 10x8x5 cm was seen. Histologically, the tumor had an admixture of heavily collagenized, hypocellular zones and more cellular myxoid nodules (Figure 2a). The tumor cells were bland spindle shaped cells arranged in a whorled or linear growth pattern (Figure 2b). The tumor

cells had scant pale eosinophilic cytoplasm and spindle-shaped to ovoid-shaped nuclei. Nucleoli were absent or indistinct, and only 1-2 mitoses per 50 high-power fields were seen.

Immunohistochemically, the neoplastic cells were stained strongly and were diffusely positive for vimentin, but did not show immunoreactivity to smooth muscle actin, muscle specific actin, Desmin, S-100, Pankeratin, EMA, CD34, CD23, CD35, CD21, CD1a, CD68, ALK or Fascin.

Pathological diagnosis was made as "low-grade fibromyxoid sarcoma". There were no metastatic lymph nodes. Her postoperative course was uncomplicated and chemotherapy or radiotherapy wasn't given. She has remained well with no evidence of disease 2 years later.

Discussion

Low grade fibromyxoid sarcomas (LGFMS) are rare seen variants of fibrosarcomas which are indolent malign mesenchymal tumors. LGFMS's are generally seen in young, but it's reported between ages of 3 to 78 at various regions of body [1]. It was first described by Evans in 1987 [3]. LGFMS's generally originated from deep soft tissue and grow from fibroblasts and collagen. They are mostly seen at lower extremities, especially at thigh, also at axilla, shoulder, inguinal region, mediastinum and intestine. Lung is a rare localization site of these tumors. To date, two cases within the lung were reported [2].

In radiological work up, at chest x-ray, fibromyxoid sarcomas are seen as large, peripheric and well bordered masses like other primer sarcomas. Although they can be seen as large heterogeneous masses, they can also be seen as solitary pulmonary nodule or a central endobronchial tumor. As other bronchial carcinomas, Thorax CT scans demonstrate local invasion and relationship with nearby tissues well.

The gross findings of LGFMS include a well circumscribed, oval to round mass with a thin, fibrous pseudocapsule. The cut surface

shows whorled, white-gray, firm and fibrous consistency with homogenous appearance [1]. Microscopically, LGFMS typically shows an admixture of heavily collagenized, hypocellular zones and more cellular myxoid nodules. There is a proliferation of bland-appearance spindle tumor cells with a whorled or linear arrangement. The tumor cells have poorly defined, pale eosinophilic cytoplasm and round to ovoid nuclei. Nucleoli are usually absent or indistinct. Mitotic figures tend to be absent or sparse.

Immunohistochemical staining has been reported by a number of authors, with some conflicting results. LGFMS typically expresses only vimentin. Some cases show focal positivity of smooth muscle actin, which is attributed to focal myofibroblastic differentiation. LGFMS were reported to be negative for desmin, S-100 protein, cy-

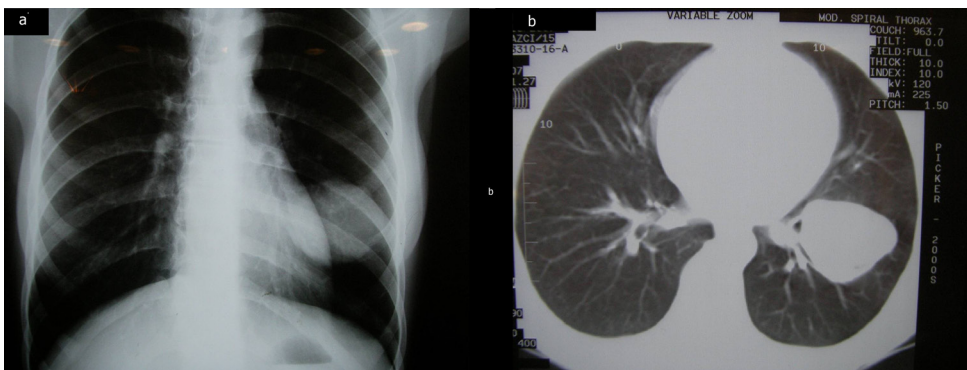


Figure 1. Chest X-ray showed homogenous, oval-shaped mass lesion on the left lower zone (A), Thorax CT revealed homogenous mass near the fissure, sized 8x10 cm on the left lower lobe superior segment (B).

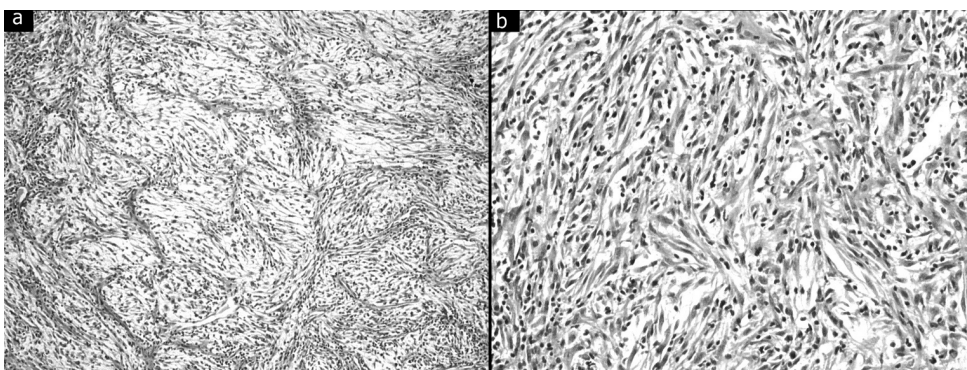


Figure 2. Low-grade fibromyxoid sarcoma (LGFMS), showing bland fibroblasts arranged in whorled pattern. (Hematoxylin-eosin, original magnification, x200) (A), At higher magnification, the tumor cells are bland spindle-shaped cells with no nuclear pleomorphism or mitotic figures (Hematoxylin-eosin, original magnification, x400) (B).

keratin, EMA, CD34 and CD31. However, a recent case series showed that most LGFMS's showed immunoreactivity to EMA, at least focally, CD99 and bcl-2. In our case, the tumor cells showed strong staining and were diffusely positive for vimentin, bcl-2 and CD99, but did not show immunoreactivity to smooth muscle actin, desmin, S-100 protein, cytokeratin, EMA, CD34 or CD68.

These tumors are characterized by a proliferation of rather bland spindle cells, with fibromyxoid areas. Several investigators have identified a characteristic balanced t(7;16)(q34;p11) translocation in LGFMS and also in hyalinizing spindle cell tumor with giant rosettes, supporting the view that these two different morphologies represent the same neoplastic process [4,5].

Diagnosis of LGFMS is still difficult because of its bland-looking histologic features that can potentially be confused with other benign or low-grade spindle cell proliferations with myxoid morphologies. There are several related neoplasms that are more commonly observed, including low-grade myxofibrosarcoma, perineurioma, myxoid neurofibroma, myxoid solitary fibrous tumor, and fibromatosis. Low-grade myxofibrosarcoma exhibits a more uniform myxoid stroma and more cellular atypia, but lacks areas of fibrous stroma or a whorled arrangement of tumor cells. Perineurioma may have fibrous and myxoid areas and is diffusely positive for EMA. Neurofibroma shows more slender wavy nuclei and expresses S-100. Myxoid solitary fibrous tumor is uniformly immunoreactive for CD34. Fibromatosis also has a more fascicular architecture, and can resemble LGFMS. Fibromatosis is characterized by clonal myofibroblast proliferation and has somatic β -catenin or adenomatous polyposis coli gene mutations that lead to intranuclear accumulation of β -catenin [6]. Additionally, in differential diagnosis, pulmonary metastases of extrapulmonary sarcomas should be excluded.

As all tumors originate from soft tissues, the most important prognostic factors at fibrosarcoma are resectability and the grade of tumor. Local recurrence rate is very high at segmentectomy or wedge resection. At an average of 65% cases come with recurrence after 6 months to 50 years, and most of them had multiple recurrences. Another important factor affecting survival is the size of tumor. Survival time of the patients with size of tumor less than 5 cm is more longer [7].

There is no need of additional therapy for patients underwent complete resection with no lymph node metastasis. On the other hand adjuvan radiotherapy and chemotherapy is acquired for incomplete resection and lymph node metastasis. Lobectomy was performed to our patient. In pathologic examination lymph nodes were reactive and bronchial surgical margin was negative. So no additional therapy was planned for the patient. However for high grade fibromyxoid tumors even with a complete resection margins, systemic adjuvan chemotherapy should be scheduled because of subclinic and microscopic metastases could be occurred or can be misdiagnosed at surgery [8].

References

1. Bacha EA, Wright CD, Grillo HC, Wain JC, Moncure A, Keel SB, et al. Surgical treatment of primary pulmonary sarcomas. *Eur J Cardiothorac Surg* 1999; 15:456-60
2. Magro G, Fraggetta F, Manusia M, Mingrino A. Hyalinizing spindle cell tumor with giant rosettes: a previously undescribed lesion of the lung. *Am J Surg Pathol* 1998; 22:1431-3.
3. Evans HL. Low-grade fibromyxoid sarcoma : a report of 12 cases. *Am J Surg Pathol* 1993; 17:595-600
4. Panagopoulos I, Storlazzi CT, Fletcher CD, Fletcher JA, Nascimento A, Domanski HA, et al. The chimeric FUS/CREB3L2 gene is specific for low-grade fibromyxoid sarcoma. *Genes Chromosomes Cancer* 2004;40:218-228.
5. Storlazzi CT, Mertens F, Nascimento A, Isaksson M, Wejde J, Brosjo O, et al. Fusion of the FUS and BBF2H7 genes in low grade fibromyxoid sarcoma. *Hum Mol*

Genet 2003; 12:2349-2358.

6. Bhattacharya B, Dilworth HP, Iacobuzio-Donahue C, Ricci F, Weber K, Furlong MA, et al. Nuclear beta-catenin expression distinguishes deep fibromatosis from other benign and malignant fibroblastic and myofibroblastic lesions. *Am J Surg Pathol* 2005; 29:653-9.
7. Porte HL, Metois DG, Leroy X, Conti M, Gosselin B, Wurtz A. Surgical treatment of primary sarcoma of the lung. *Eur J Cardiothorac Surg* 2000; 18:136-42.
8. Shidham VB, Ayala GE, Lahaniatis JE, Garcia FU. Low-grade fibromyxoid sarcoma: clinicopathologic case report with review of the literature. *Am J Clin Oncol* 1999; 22(2):150-5.